


**AMES DENTAL COLLEGE AND HOSPITAL**  
**DEPARTMENT OF ORALPATHOLOGY**  
**SPECIAL CASE**



# AME'S DENTAL COLLEGE & HOSPITAL, RAICHUR

(Recognized by Dental Council of India, New Delhi)

(Affiliated to Rajiv Gandhi University of Health Sciences, Bangalore)

RAICHUR - 584 101. Ph: 08532-240718, Fax: 08532-240718

Website: [www.amedc.org.in](http://www.amedc.org.in)

---

## DEPARTMENT OF ORAL AND MAXILLOFACIAL PATHOLOGY

### BIOPSY REPORT

**NAME :** Gopala krishna

**DATE :** 13/05/2026

**AGE / SEX :** 65/M

**O.P.D. No :**

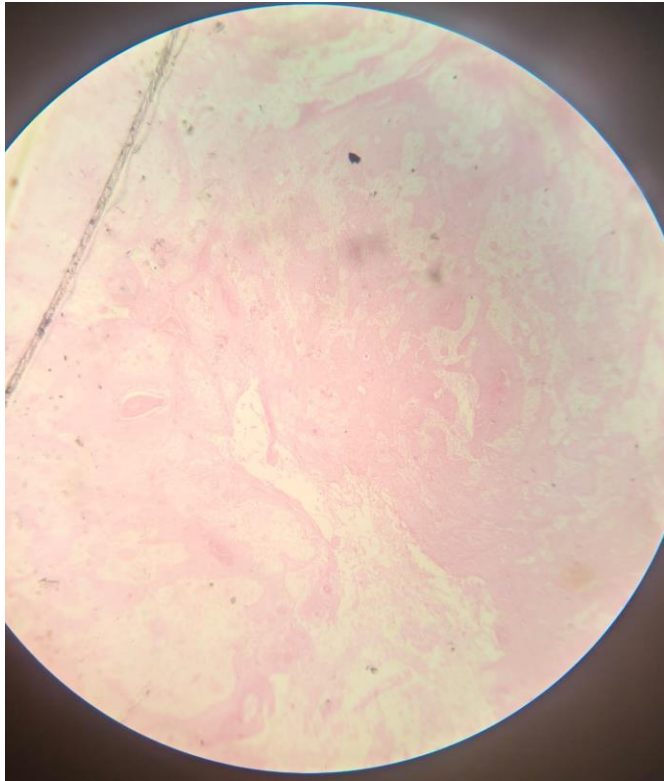
**Biopsy No :** 170/26

**Referred by :** DR Siddanagowda

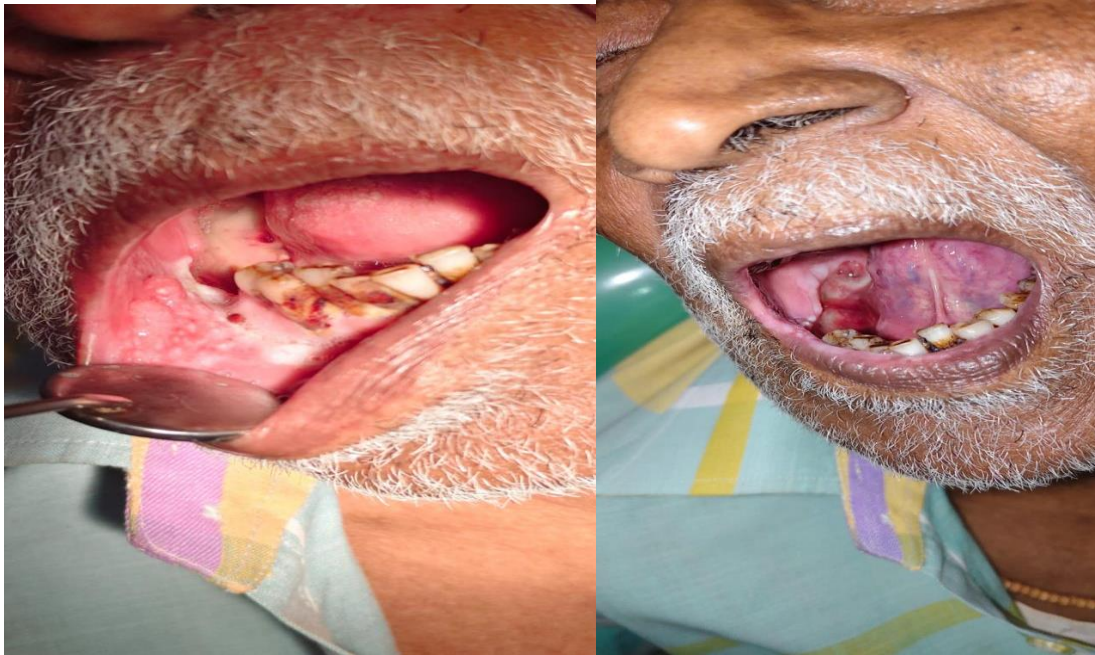**MACROSCOPIC FINDINGS :** Received formalin fixed specimen measuring 1×1 cms greyish white in color ,firm in consistency sent for processing

**MICROSCOPIC FINDINGS :** Stained section shows hyperplasia of stratified squamous epithelium, with dysplastic epithelial islands showing altered nuclear cytoplasmic ratio, nuclear pleomorphism, mitotic figures and epithelium also shows few keratin pearls. Underlying connective tissue shows few muscle cells, adipose cells and collagen fibers are seen.

**IMPRESSION :** Co-relating the clinical features above histopathological features are suggestive of **WELL DIFFERENTIATED SQUAMOUS CELL CARCINOMA**



**HISTOPATHOLOGY**



**LESION ON ALVEOLAR MUCOSA**